

Irritational Fibroma of Lower Labial Mucosa: A Case Report

Deepali Jain, Ranjana Mohan, Swati Sinha, Vikram Deep Singh, Akanksha Singh

Department of Periodontology, Teerthankar Mahaveer Dental College & Research Center, Moradabad, Uttar Pradesh, India

ABSTRACT

Traumatic or irritational fibroma is a general benign exophytic tumor or neoplasm of fibrous connective tissue origin that can be considered a reactionary connective tissue hyperplasia in response to trauma and irritation. They are clinically marked by solid well-demarcated rounded, sessile, or pedunculated growths covered by normal mucosa and are a relatively uncommon lesion. Local trauma can generate ulceration of these lesions. They are usually seen on the buccal mucosa but can also occur at any intra-oral site. These lesions are more common in adults and can befall at any age. A malignant transformation in such fibroma or lesion is uncommon. Simple, complete excision and removal of the cause of irritation are the preferred treatment. It is the common type of lesion for which the treatment of choice is complete surgical excision.

Key words: Fibroma, lower mucosa, soft tissue

CASE REPORT

A female patient of 25 years old reported to the Department of Periodontology with a complaint of gingival overgrowth in the lower lip region since 6-7 months. On examination, it was an asymptomatic nodular lesion of mucosal color on the lower lip buccal mucosa in the region of 32 and 33 [Figure 1]. The asymptomatic lesion increased gradually in size when it was the first noticed by the patient. There was neither history of bleeding from the lesion nor any history of trauma. On clinical examination, the lesion revealed a single, pink, sessile, firm, and smooth surfaced nodule of size 0.9 mm × 0.4 mm × 0.2 mm intra-oral lower labial mucosa. By history and clinical findings, a provisional diagnosis of irritation fibroma was given. The list of differential diagnosis included chronic fibrous epulis, peripheral giant

cell granuloma, osteosarcoma, chondrosarcoma, pyogenic granuloma, and peripheral odontogenic fibroma. Complete hemogram revealed all blood cell counts within normal limits. As the patient reported discomfort during eating and while speaking, it was decided to go for an excisional biopsy performed under local anesthesia using a scalpel [Figure 2]. The surgical exposure revealed that the lesion was well demarcated from buccal mucosa permitting relatively easy separation of a tumor from its soft tissue bed and suturing was done [Figure 3]. The excised tissue [Figure 4] was sent to the Department of Oral Pathology for histopathological examination. Thus, a final diagnosis of irritation fibroma was given [Figure 5].

DISCUSSION

Irritational fibromas are the most common benign soft tissue tumors seen in the oral cavity. It is also known as focal fibrous hyperplasia, oral fibroma or as fibromatosis. It is characterized by fibrous tissue and mineralized material that does not fuse with its surroundings. Thus, the lesion is demarcated or encapsulated (rhinology). Irritational fibromas show variable amounts of woven and lamellar bone trabeculae and osteoblasts may rim the trabeculae. A psammomatoid

Access this article online	
Publisher 	Website: www.renupublishers.com
	DOI: 10.5958/2394-4196.2016.00005.4□□

Address for Correspondence:

Dr. Deepali Jain, Department of Periodontology, Teerthankar Mahaveer Dental College & Research Center, Moradabad, Uttar Pradesh, India. E-mail: drdeepali1026@gmail.com

Submission: 12 Jan 2016; **Revision:** 22 Feb 2016; **Acceptance:** 23 Mar 2016

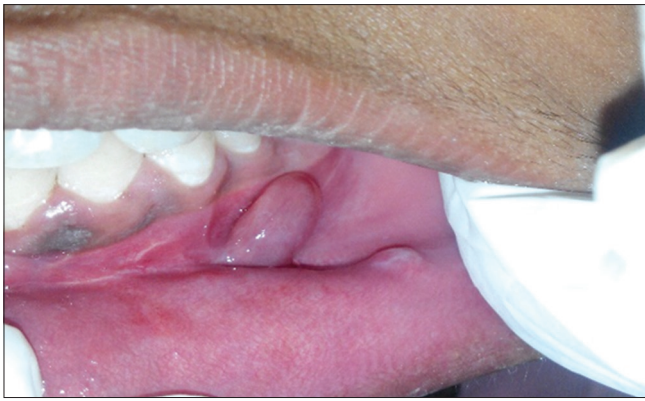

Figure 1: Well circumscribed lesion

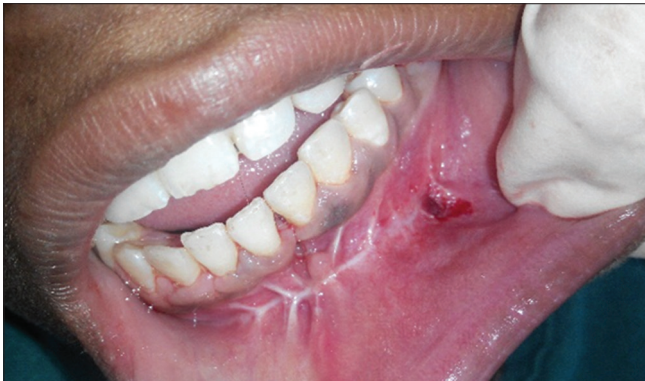

Figure 2: Complete excision of lesion

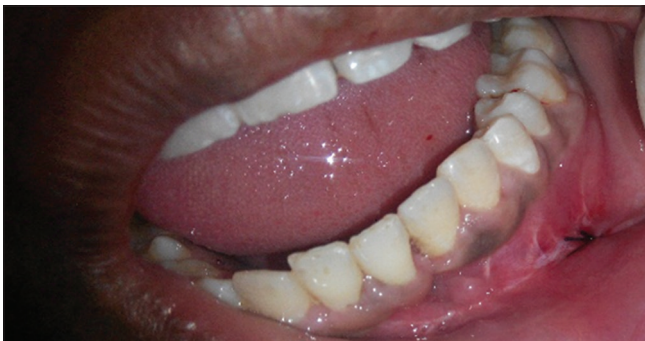

Figure 3: Suturing done

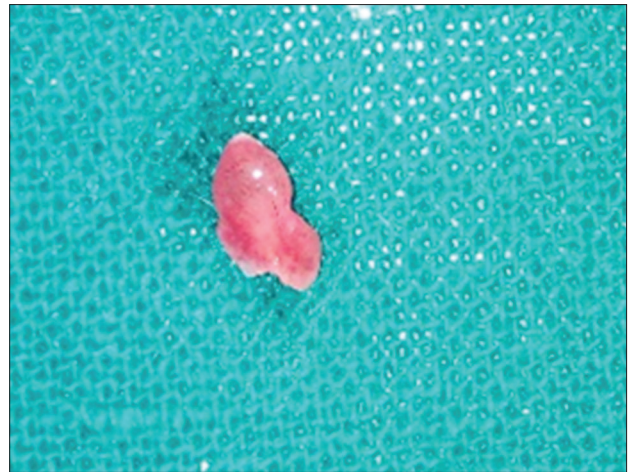

Figure 4: Gross specimen of excised tissue

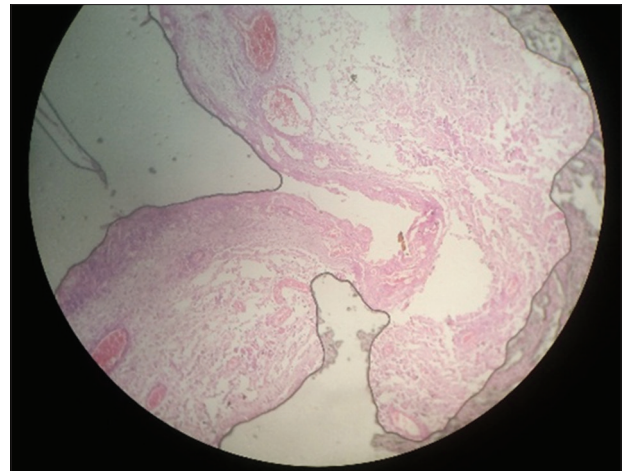


Figure 5: Histopathological examination

variant is a subtype of irritational fibroma with distinctive histomorphological and clinical features.^[1,2] Histologically, spherical ossicles with irregular seams of osteoid in a highly cellular fibrous tissue, separated by fibrous tissue were observed.^[1] It is a slowly progressive lesion with the potential to create a sizeable defect in the orbit and the sinonasal tract. In the WHO classification of jaw tumors, juvenile aggressive irritational fibroma is divided into two types: Juvenile psammomatoid irritational fibroma and juvenile trabecular irritational fibroma.^[3] The juvenile psammomatoid irritational fibroma mainly involves the orbit and paranasal sinuses seen in older people. Juvenile trabecular irritational fibroma mainly affects the jaw bones in children and adolescents.^[1]

Psammomatoid irritational fibroma was initially described by Gogl as early as in 1949.^[4] In 1985, Margo described psammomatoid juvenile irritational fibroma as a distinctive solitary fibrous osseous lesion of young adults. Psammomatoid juvenile irritational fibroma is not classified under osseous tumors of the jaw in the Armed Forces Institute of Pathology book.

Afflicted individuals tend to be young. In general, the patients with psammomatoid irritational fibroma are a few years older than those with trabecular psammomatoid irritational fibroma. But as in the case of trabecular juvenile irritational fibroma, there is no sex predilection. The majority of psammomatoid irritational fibromas originate in the paranasal sinuses and about 10% have been reported to originate in the calvarium. In this study, the tumor was in the paranasal sinuses. Clinically, it presents as proptosis, visual complaints, nasal obstruction, ptosis, and papilledema.

Confusion between trabecular juvenile irritational fibroma and psammomatoid irritational fibroma is due to the use

of term juvenile irritational fibroma to describe these two entities. Trabecular juvenile irritational fibroma is trabecular, i.e., favors gnathic bones, whereas psammomatoid juvenile irritational fibroma is psammomatoid, i.e., involves periorbital bones. This case fits into the criteria. The patient came with a recurrent lesion after 6 months.

Campos and Gomez^[5] and Weathers and Campbell^[6] suggested that the stellate and multinucleate cells of giant cell fibroma have a fibroblast phenotype and are large atypical fibroblasts. A variety of cutaneous lesions such as the fibrous papule of the nose, ungual fibroma, acral fibrokeratoma and acral angiofibroma containing similar stellate mono, and multinuclear giant cells have been described in humans. The main similarity between this group of cutaneous lesions and the giant cell fibroma is their histologic appearance. The differences are that the skin lesions have not been associated with oral lesions, and they do not show same frequency of occurrence and age distribution.

Irritational fibromas may occur at any age but are more common in young adults. A variant of irritational fibroma, juvenile (aggressive) irritational fibroma, has been described in children and young adults who are younger than 15 years of age.^[7] Females are more commonly affected than males and anterior maxilla is the most common location of involvement where lesion predominates in the second decade of life.^[4] Hormonal influences may play a role, given the higher incidence of peripheral irritational fibroma among females, increasing occurrence in the second decade, and declining incidence after the third decade.^[5-8] In the present case, anterior maxilla was involved, and the patient was almost at the end of his first decade. However, interestingly in our case, the patient was male although it is seen more commonly in females.

Histologically, few benign lesions are also fibro-osseous in nature. They are composed of cellular fibrous tissue with areas of fibrovascular tissue that often contain an inflammatory component with abundant plasma cells. Ossification is usually seen in the cellular zone and shows considerable variations both quantitatively and qualitatively. From small rounded calcified deposits to large trabecular bone areas surrounded by osteoblasts may be observed.^[9-11] The predominant cell of this lesion is a bland spindle cell. Mitotic figures are rare. Admixed in the fibrous background are irregularly shaped osseous islands. The histopathologic hematoxylin and eosin stained section of lesion revealed a well-circumscribed, capsulated mass; the capsule was fibrous and thinned out at places. The subcapsular area comprised interconnected bony trabeculae encasing plump osteocytes with most of the trabeculae exhibiting osteoblastic rimming. Concentric lamellated and spherical ossicles were seen with a basophilic center and peripheral eosinophilic mass. The fibrous tissue is of varying cellularity with few chronic inflammatory cells.

The most common site for such benign lesion is buccal mucosa, tongue, and lower labial mucosa. On clinical inspection appearance of such lesion is lighter in color than the surrounding normal tissue with surface often appearing white because of hyperkeratosis or with surface ulceration caused by secondary trauma.^[11-13]

Bad oral habits lead to imbalance in orofacial muscular when repeated excessively becomes harmful, contributing to associate with alterations in bone growth, dental malposition, and dentofacial abnormalities. Biting, licking, or sucking of lips and cheeks are frequently accompanied by chapping, dryness, erosion, irritation of one of both lips, and/or vermilion borders.^[11-13]

The treatment of choice for peripheral irritational fibroma is local resection with peripheral and deep margins including both the periodontal ligament and the affected periosteal component.^[2,9] In addition, elimination of the local etiological factors such as plaque and tartar is required.^[2,8] The teeth associated with peripheral irritational fibroma are generally not mobile, though there have been reports of migration secondary to bone loss.^[2,9]

CONCLUSION

Irritational fibroma is a benign lesion with significant growth potential. This lesion is mainly characterized by slow-growing soft tissue nodule primarily involving the buccal mucosa, maxilla, and mandible in the second decade of life. Many patients do not approach a dentist as it is mainly asymptomatic during initial stages until the size increases considerably. Conservative excisional biopsy is curative, and its findings are diagnostic; however, recurrence is possible if the exposure to the offending irritant persists. In rural India due to lack of proper guidance, early diagnosis and prompt treatment of such lesions is not possible. Treatment consists of complete surgical excision of the lesion, and these lesions have considerable reoccurrence rates hence requiring close post-operative follow-up visits.

REFERENCES

1. Farquhar T, Maclellan J, Dymont H, Anderson RD. Peripheral irritational fibroma: A case report. *J Can Dent Assoc* 2008;74:809-12.
2. Kumar SK, Ram S, Jorgensen MG, Shuler CF, Sedghizadeh PP. Multicentric peripheral ossifying fibroma. *J Oral Sci* 2006;48:239-43.
3. García de Marcos JA, García de Marcos MJ, Arroyo Rodríguez S, Chiarri Rodrigo J, Poblet E. Peripheral ossifying fibroma: A clinical and immunohistochemical study of four cases. *J Oral Sci* 2010;52:95-9.
4. Bhaskar SN, Jacoway JR. Peripheral fibroma and peripheral fibroma with calcification: Report of 376 cases. *J Am Dent Assoc* 1966;73:1312-20.
5. Campos E, Gomez RS. Immunocytochemical study of giant cell fibroma. *Braz Dent J* 1999;10:89-92.
6. Weathers DR, Campbell WG. Ultrastructure of the giant-cell

- fibroma of the oral mucosa. *Oral Surg Oral Med Oral Pathol* 1974;38:550-61.
7. Sarode SC, Sarode GS, Waknis P, Patil A, Jashika M. Juvenile psammomatoid ossifying fibroma: A review. *Oral Oncol* 2011;47:1110-6.
 8. Smith SF, Newman L, Walker DM, Papadopoulos H. Juvenile aggressive psammomatoid ossifying fibroma: An interesting, challenging, and unusual case report and review of the literature. *J Oral Maxillofac Surg* 2009;67:200-6.
 9. Rangil JS, Silvestre FJ, Bernal JR. Cemento-irritational fibroma of the mandible: Presentation of a case and review of the literature. *J Clin Exp Dent* 2011;3:e66-9.
 10. Pal S, Hegde S, Ajil V. The varying clinical presentations of peripheral ossifying fibroma: A report of three cases. *Rev Odonto Cien* 2012;27:251-5.
 11. Dhanuthai K, Banrai M, Limpanaputtajak S. A retrospective study of paediatric oral lesions from Thailand. *Int J Paediatr Dent* 2007;17:248-53.
 12. Chi D, Kanellis M, Himadi E, Asselin ME. Lip biting in a pediatric dental patient after dental local anesthesia: A case report. *J Pediatr Nurs* 2008;23:490-3.
 13. Leache EB, Naranjo AM, Couso R, Conzalez DG. Are the oral piercing important in the clinic? *Dent Pract* 2006;1:45-9.

How to cite this article: Jain D, Mohan R, Sinha S, Singh VD, Singh A. Irritational Fibroma of Lower Labial Mucosa: A Case Report. *Int J Dent Med Spec* 2016;3(1):16-19.

Source of Support: None; **Conflict of Interest:** None